

Rehabilitation of the thrower's elbow

Kevin E. Wilk, PT^{a,b,*}, Michael M. Reinold, DPT, ATC, CSCS^a,
James R. Andrews, MD^{a,b,c}

^aHealthSouth Corporation, American Sports Medicine Institute, 1201 11th Avenue South, Suite 100,
Birmingham, AL 35205, USA

^bTampa Bay Devil Rays Baseball Organization, One Tropicana Drive, Tampa Bay, FL 33705, USA

^cAlabama Orthopedic and Sports Medicine Center, 1201 11th Avenue South, Suite 200,
Birmingham, AL 35205, USA

Injuries to the elbow occur often in the overhead athlete. The repetitive overhead motion involved in throwing is responsible for unique and sport-specific patterns of elbow injuries. These are caused by chronic stress overload or repetitive microtraumatic stress observed during the overhead pitching motion as the elbow extends at over 2300°/s, producing a medial shear force of 300 N and compressive force of 900 N [1,2]. In addition, the valgus stress applied to the elbow during the acceleration phase of throwing is 64 Nm [1,2], which exceeds the ultimate tensile strength of the ulnar collateral ligament (UCL) [3]. Thus, the medial aspect of the elbow undergoes tremendous tension (distraction) forces, and the lateral aspect is forcefully compressed during the throw.

The overhead athlete is susceptible to specific elbow injuries. A number of forces act on the elbow during the act of throwing [1,2], including valgus stress with tension across the medial aspect of the elbow. These forces are maximal during the acceleration phase of throwing. Compression forces are also applied to the lateral aspect of the elbow during the throwing motion. The posterior compartment is subject to tensile, compressive, and torsional forces during acceleration and deceleration phases. This may result in valgus extension overload within the posterior compartment, potentially leading to osteophyte formation, stress fractures of the olecranon, or physeal injury [4,5].

* Corresponding author. HealthSouth Corporation, American Sports Medicine Institute, 1201 11th Avenue South, Suite 100, Birmingham, AL 35205.

E-mail address: kevin.wilk@healthsouth.com (K.E. Wilk).

This article provides an overview of general rehabilitation principles for the thrower's elbow. Specific nonoperative and postoperative treatment guidelines for the thrower's elbow are also discussed.

General rehabilitation guidelines

Rehabilitation following elbow injury or elbow surgery follows a sequential and progressive multiphased approach. The ultimate goal of elbow rehabilitation is to return the athlete to the previous functional level as quickly and safely as possible. This section provides an overview of the rehabilitation process following elbow injury, outlined in [Box 1](#), and surgery, outlined in [Box 2](#). Rehabilitation protocols for specific pathologies will follow.

Phase I—immediate motion phase

The first phase of elbow rehabilitation is the immediate motion phase. The goals of this phase are to minimize the effects of immobilization, to reestablish non-painful ROM, to decrease pain and inflammation, and to retard muscular atrophy.

Early range-of-motion activities are performed to nourish the articular cartilage and assist in the synthesis, alignment, and organization of collagen tissue [6–14]. ROM activities are performed for all planes of elbow and wrist motions to prevent the formation of scar tissue and adhesions. Active-assisted and passive ROM exercises are performed for the humeroulnar and joint to restore flexion/extension and supination/pronation for the humeroradial and radialulnar joints. Reestablishing full elbow extension, or preinjury motion, is the primary goal of early ROM activities, in order to minimize the occurrence of elbow flexion contractures [15–17]. The preoperative elbow motion must be carefully assessed and recorded. The athlete should be asked whether or not full elbow extension has occurred in the past 2 to 3 years. Postoperative ROM is often related to preoperative motion, especially in the case of UCL reconstruction. This can be a deleterious side effect for the overhead athlete. The elbow is predisposed to flexion contractures, due to the intimate congruency of the joint articulations, the tightness of the joint capsule, and the tendency of the anterior capsule to develop adhesions following injury [14]. The brachialis muscle also attaches to the capsule and crosses the elbow joint before becoming a tendinous structure. Injury to the elbow may cause excessive scar tissue formation of the brachialis muscle and functional splinting of the elbow [14].

In addition to ROM exercises, joint mobilizations may be performed as tolerated to minimize the occurrence of joint contractures. Posterior glides with oscillations are performed at end range of motion to assist in regaining full elbow extension. Initially Grade I and II mobilizations are used, progressing to aggressive mobilization techniques at end range of motion during later stages of rehabilitation, when symptoms have subsided. Joint mobilization must include the radiocapitallor and radioulnar joints.

Box 1. Nonoperative rehabilitation program for elbow injuries

Acute phase (week 1)

Goals: improve motion, diminish pain and inflammation, retard muscle atrophy

Exercises

1. Stretching for wrist and elbow joint; stretches for shoulder joint
2. Strengthening exercises: isometrics for wrist, elbow, and shoulder musculature
3. Pain and inflammation control cryotherapy, high voltage galvanic stimulation (HVGS), ultrasound, and whirlpool

Subacute phase (weeks 2–4)

Goals: normalize motion; improve muscular strength, power, and endurance

Week 2

1. Initiate isotonic strengthening for wrist and elbow muscles.
2. Initiate exercise tubing exercises for shoulder.
3. Continue use of cryotherapy, etc.

Week 3

1. Initiate rhythmic stabilization drills for elbow and shoulder joint.
2. Progress isotonic strengthening for entire upper extremity.
3. Initiate isokinetic strengthening exercises for elbow flexion/extension.

Week 4

1. Initiate thrower's ten program.
2. Emphasize eccentric biceps work, concentric triceps work, and wrist flexor work.
3. Program endurance training.
4. Initiate light plyometric drills.
5. Initiate swinging drills.

Intermediate phase (weeks 4–6)

Goals: preparation of athlete for return to functional activities

Criteria to progress to advanced phase

1. Full nonpainful range of motion (ROM)
2. No pain or tenderness
3. Satisfactory isokinetic test
4. Satisfactory clinical examination

Weeks 4–5

1. Continue strengthening exercises, endurance drills, and flexibility exercises daily.
2. Thrower's ten program
3. Progress plyometric drills.
4. Emphasize maintenance program based on pathology.
5. Progress swinging drills (ie, hitting).

Weeks 6–8

1. Initiate interval sport program once determined by physician.

Phase I throwing program

*Return-to-activity phase (weeks 6–9)**Weeks 6 through 9*

Return to play depends on thrower's condition and progress; physician will determine when it is safe.

1. Continue strengthening program thrower's ten program.
2. Continue flexibility program.
3. Progress functional drills to unrestricted play.

If the patient continues to have difficulty achieving full extension using ROM and mobilization techniques, a low load, long duration (LLLD) stretch may be performed to produce a deformation (crep) of the collagen tissue, resulting in tissue elongation [18–21]. The authors have found this technique to be extremely beneficial for regaining full elbow extension. The patient lies supine with a towel roll or foam placed under the distal brachium to act as a cushion and fulcrum. Light-resistance exercise tubing is applied to the wrist of the patient and secured to the table or a dumbbell on the ground (Fig. 1). The patient is instructed to relax as much as possible for 10 to 12 minutes. The amount of resistance applied should be of low magnitude, to enable the patient to perform the stretch for the entire duration without pain or muscle spasm—this technique should impart a low-load but long-duration stretch.

The aggressiveness of stretching and mobilization techniques is dictated based on healing constraints of involved tissues, such as specific pathology/surgery and

Box 2. Postoperative rehabilitative protocol for elbow arthroscopy

Initial phase (week 1)

Goals: Full wrist and elbow ROM; decrease swelling; decrease pain, retardation, or muscle atrophy

Day of surgery

1. Begin gently moving elbow in bulky dressing.

Postoperative days 1 and 2

1. Remove bulky dressing and replace with elastic bandages.
2. Immediate postoperative hand, wrist, and elbow exercises
 - Putty/grip strengthening
 - Wrist flexor stretching
 - Wrist extensor stretching
 - Wrist curls
 - Reverse wrist curls
 - Neutral wrist curls
 - Pronation/supination
 - AIAAROM elbow extension/flexion

Postoperative days 3–7

1. Passive range of motion (PROM) elbow extension/flexion (motion to tolerance)
2. Begin progressive resisted exercises (PRE) exercises with 1 lb weight.
 - Wrist curls
 - Reverse wrist curls
 - Neutral wrist curls
 - Pronation/supination
 - Broomstick roll-up

Intermediate phase (weeks 2–4)

Goals: improve muscular strength and endurance, normalize joint arthrokinematics

Week 2: ROM exercises (overpressure into extension)

1. Addition of biceps curl and triceps extension
2. Continue to progress PRE weight and repetitions as tolerable.

Week 3

1. Initiate biceps and biceps eccentric exercise program.
2. Initiate rotator cuff exercises program.
 - External rotators
 - Internal rotators
 - Deltoid
 - Supraspinatus
 - Scapulothoracic strengthening

Advanced phase (weeks 4–8)

Goal: Preparation of athlete for return to functional activities

Criteria to progress to advanced phase:

1. Full nonpainful ROM
2. No pain or tenderness
3. Isokinetic test that fulfills criteria to throw
4. Satisfactory clinical examination

Weeks 4–6

1. Continue maintenance program, emphasizing muscular strength, endurance, and flexibility.
2. Initiate interval throwing program phase.

Weeks 7–8

1. Continue program
2. Progress throwing program as tolerated.

the amount of motion and end feel. If the patient presents with a decrease in motion and hard end feel without pain, aggressive stretching and mobilization technique can be used. Conversely, a patient exhibiting pain before resistance or an empty end feel will be progressed slowly with gentle stretching.

Another goal of this phase is to decrease the patient's pain and inflammation. Grade I and II mobilization techniques may also be used to neuromodulate pain by stimulating Type I and Type II articular receptors [22,23]. Cryotherapy and high-voltage stimulation may be performed as required to further assist in reducing pain and inflammation. Once the acute inflammatory response has subsided, moist heat, warm whirlpool, and ultrasound may be used at the onset of treatment in order to prepare the tissue for stretching and to improve the extensibility of the capsule and musculotendinous structures. In addition, joint mobilization glides are increased to Grade III and IV mobilizations.

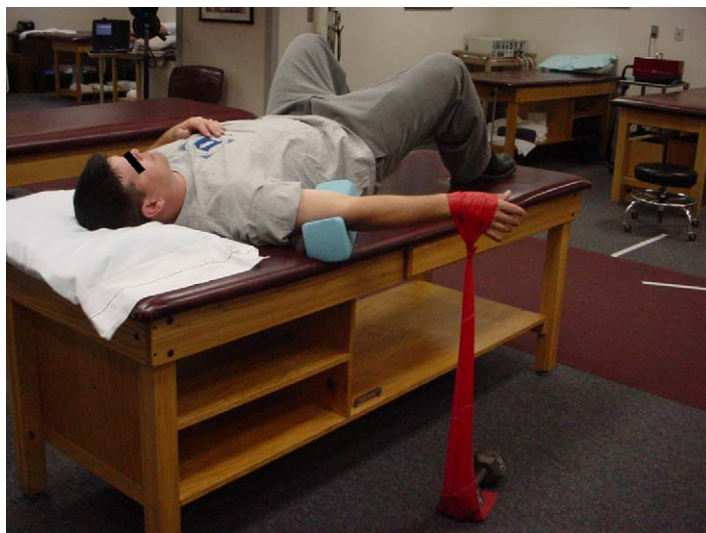

Fig. 1. A low-load, long-duration stretch into elbow extension is performed using light resistance.

The early phases of rehabilitation also focus on voluntary activation of muscle and retarding muscular atrophy. Subpainful and submaximal isometrics are performed initially for the elbow flexor and extensor, as well as for the wrist flexor, extensor, pronator, and supinator muscle groups. Shoulder isometrics may also be performed during this phase, with caution against internal and external rotation exercises if they are painful. Alternating rhythmic stabilization drills for shoulder flexion/extension/horizontal abduction/adduction, shoulder internal/external rotation, and elbow flexion/extension/supination/pronation are performed to begin reestablishing proprioception and neuromuscular control of the upper extremity.

Phase II—intermediate phase

Phase II, the intermediate phase, is initiated when the patient exhibits full ROM, minimal pain and tenderness, and a good (4/5) manual muscle test of the elbow flexor and extensor musculature. The emphasis of this phase includes enhancing elbow and upper extremity mobility, improving muscular strength and endurance, and reestablishing neuromuscular control of the elbow complex.

Stretching exercises are continued to maintain full elbow and wrist range of motion. Mobilization techniques may be progressed to more aggressive Grade III techniques, as needed, to apply a stretch to the capsular tissue at end range. Flexibility is progressed during this phase to focus on wrist flexion, extension, pronation, and supination. Elbow extension and forearm pronation flexibility are of particular importance for effective performance in throwing athletes. Shoulder

Fig. 2. Thrower's ten program. (A) Diagonal pattern D2 extension. Involved hand grips tubing handle overhead and out to the side. Pull tubing down and across body to opposite side of leg; lead with thumb. (B) Diagonal pattern D2 flexion. Grip tubing handle with involved hand. Begin with arm out from side 45° and palm facing backward. After turning palm forward, flex elbow and bring arm up and over involved shoulder. Turn palm down and reverse to take arm back to starting position. (C) External rotation at 0° abduction. Stand with involved elbow at side, elbow at 90° , and arm across front of body. Grip tubing handle while other end is fixed. Pull arm out, keeping elbow at side. Return tubing slowly, with control. (D) Internal rotation at 0° abduction. Stand with involved elbow at side, fixed at 90° with shoulder rotated out. Grip tubing handle while other end is fixed. Pull arm across body, keeping elbow at side. Return tubing slowly, with control. (E) External rotation at 90° abduction. Stand with shoulder abducted 90° . Grip tubing handle while other end is fixed straight ahead, slightly lower than the shoulder. Keeping shoulder abducted, rotate shoulder back, keeping elbow at 90° . Return tubing and hand to starting position. (F) Internal rotation at 90° abduction. Stand with shoulder abducted to 90° , externally rotated 90° , and elbow bent to 90° . Keeping shoulder abducted, rotate shoulder forward, keeping elbow bent at 90° . Return tubing and hand to start position. (G) Shoulder abduction to 90° . Stand with arm at side, elbow straight, and palm against side. Raise arm to the side, palm down, until arm reaches 90° (shoulder level). (H) Scaption, external rotation. Stand with elbow straight and thumb up. Raise arm to shoulder level at 30° angle in front of body. Do not go above shoulder height. Hold 2 seconds and lower slowly. (I) Side-lying external rotation. Lie on uninvolved side, with involved arm at side of body and elbow bent to 90° . Keeping the involved elbow fixed to side, raise arm. Hold 2 seconds and lower slowly. (J) Prone horizontal abduction (neutral). Lie on table, face down, with involved arm hanging straight to the floor, and palm facing down. Raise arm out to the side, parallel to floor. Hold 2 seconds and lower slowly. (K) Prone horizontal abduction (full ER, 100° abduction). Lie on table face down, with involved arm hanging straight to floor, and thumb rotated up (hitchhiker). Raise arm out to the side with arm slightly in front of shoulder, parallel to floor. Hold 2 seconds and lower slowly. (L) Prone rowing. Lie on stomach with involved arm hanging over side of table, dumbbell in hand and elbow straight. Slowly raise arm, bending elbow, and bring dumbbell as high as possible. Hold at the top for 2 seconds, then slowly lower. (M) Prone rowing into external rotation. Lie on stomach with involved arm hanging over the side of the table, dumbbell in hand and elbow straight. Slowly raise arm, bending elbow, up to the table level. Pause 1 second, then rotate shoulder upward until dumbbell is even with the table, keeping elbow at 90° . Hold at the top for 2 seconds, then slowly lower, taking 2–3 seconds. (N) Press-ups. Seated on a chair or table, place both hands firmly on the sides of the chair or table, palm down and fingers pointed outward. Hands should be placed even with shoulders. Slowly push downward through the hands to elevate body. Hold elevated position for 2 seconds, then lower body slowly. (O) Push-ups. Start in the down position with arms in a comfortable position. Place hands no more than shoulder width apart. Push up as high as possible, rolling shoulders forward after elbows are straight. Start with a push-up into wall. Gradually progress to table top, and eventually to floor as tolerable. (P) Elbow flexion. Standing with arm against side and palm facing inward, bend elbow upward, turning palm up as you progress. Hold 2 seconds and lower slowly. (Q) Elbow extension (abduction). Raise involved arm overhead. Provide support at elbow from uninvolved hand. Straighten arm overhead. Hold 2 seconds and lower slowly. (R) Wrist extension. Supporting the forearm and with palm facing downward, raise weight in hand as far as possible. Hold for 2 seconds and lower slowly. (S) Wrist flexion. Supporting the forearm and with palm facing upward, lower weight in hand as far as possible, then curl it up as high as possible. Hold for 2 seconds and lower slowly. (T) Supination. Forearm supported on table with wrist in neutral position. Using a weight or hammer, roll wrist, taking palm up. Hold for 2 seconds and return to starting position. (U) Pronation. Forearm should be supported on a table with wrist in neutral position. Using a weight or hammer, roll wrist, taking palm down. Hold for 2 seconds and return to starting position.

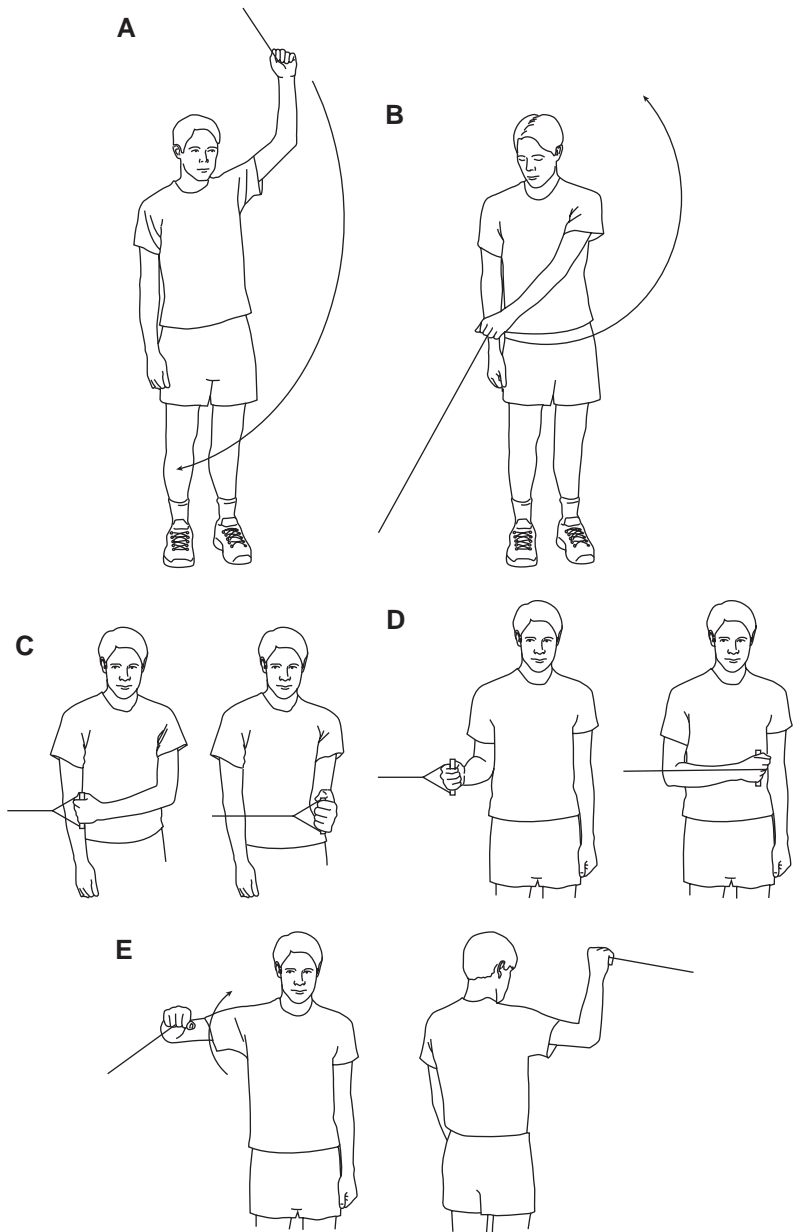


Fig. 2 (continued).

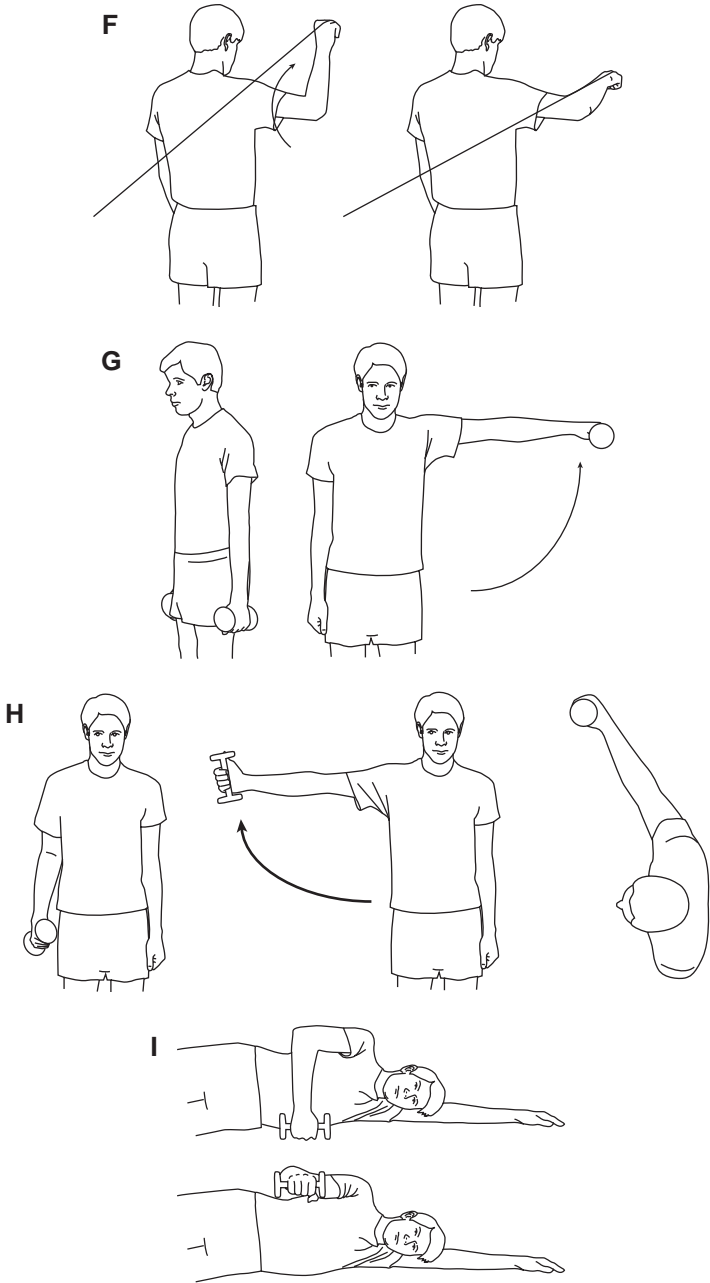


Fig. 2 (continued).

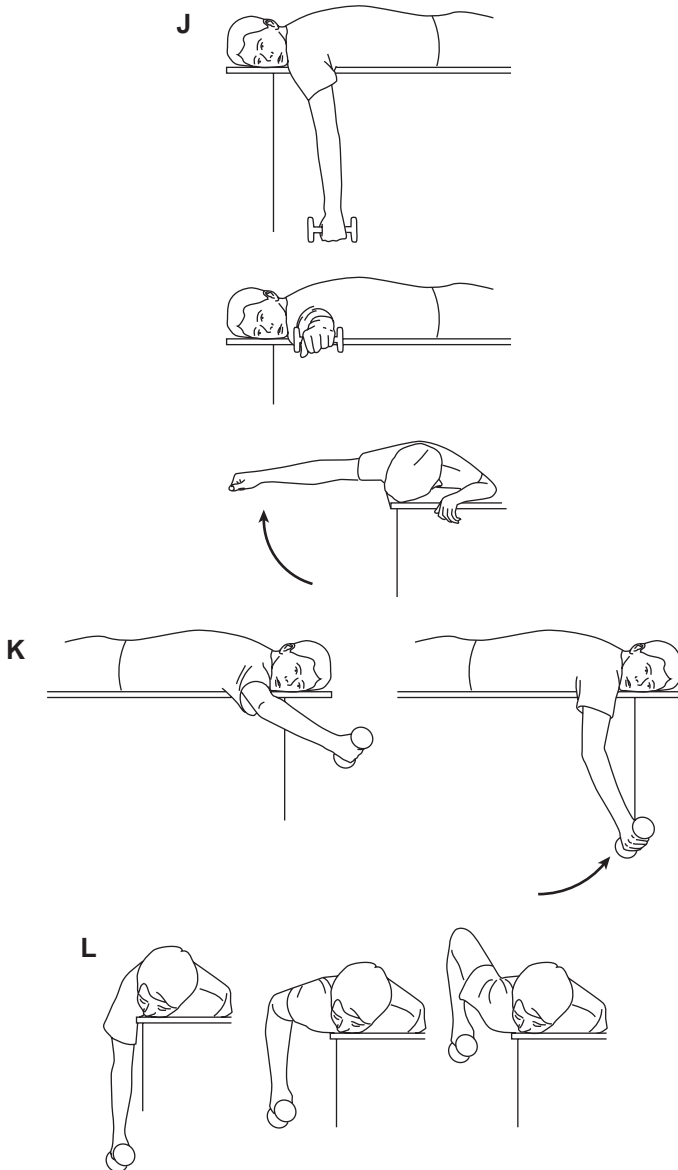


Fig. 2 (continued).

flexibility is also maintained in athletes, with emphasis on external and internal rotation at 90° of abduction, flexion, and horizontal adduction. In particular, shoulder external rotation at 90° abduction is emphasized; loss of external rotation may result in increased strain on the medial elbow structures during the overhead throwing motion. Internal rotation motion is also diligently performed.

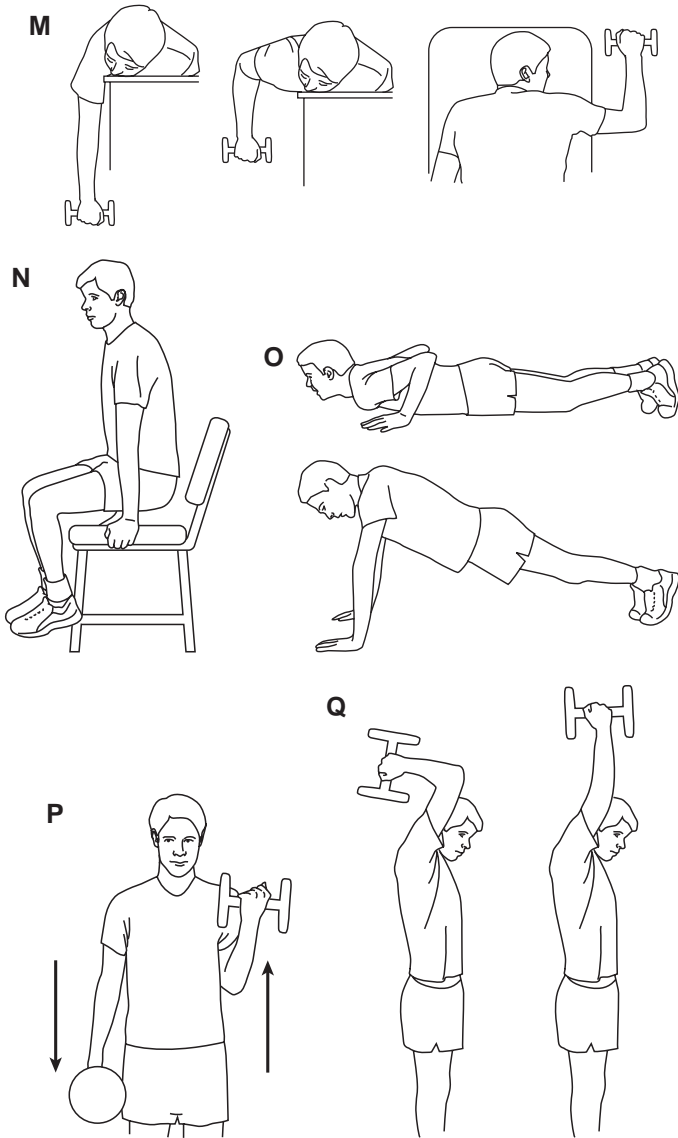


Fig. 2 (continued).

Strengthening exercises progress during this phase to include isotonic contractions, beginning with concentric and progressing to include eccentric contractions. Emphasis is placed on elbow flexion and extension, wrist flexion and extension, and forearm pronation and supination. The glenohumeral and scapulothoracic muscles are also placed on a progressive resistance program during the

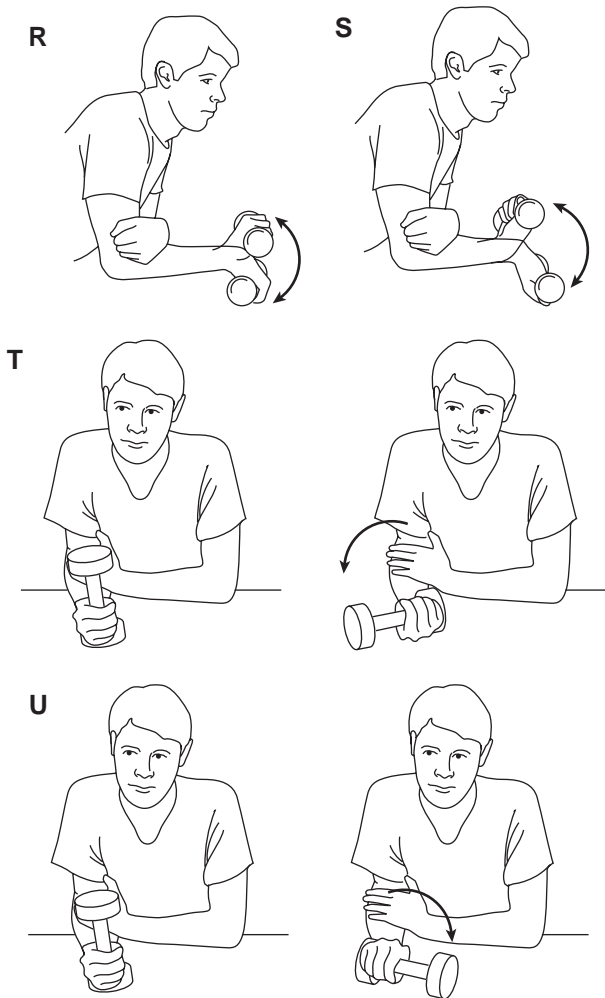


Fig. 2 (continued).

later stages of this phase. Emphasis is placed on strengthening the shoulder external rotators and scapular muscles. A complete upper-extremity strengthening program, such as the thrower's ten program (Fig. 2), may be performed.

Neuromuscular control exercises are initiated in this phase to enhance the muscles' ability to control the elbow joint during athletic activities. These exercises include proprioceptive neuromuscular facilitation exercises with rhythmic stabilizations (Fig. 3), and slow-reversal, manual-resistance, elbow/wrist flexion drills (Fig. 4).

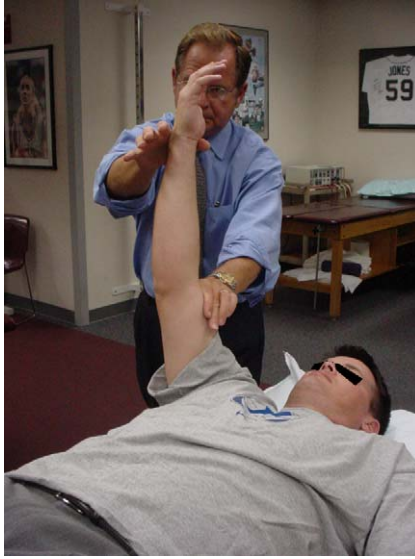

Fig. 3. Manual proprioceptive neuromuscular facilitation, upper-extremity D2 patterns with rhythmic stabilization.

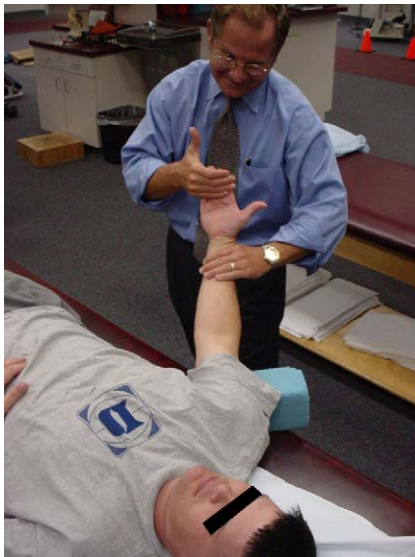

Fig. 4. Manual concentric and eccentric resistance exercise for the elbow flexors and wrist flexor-pronators.

Phase III—advanced strengthening phase

The third phase involves a progression of activities to prepare the athlete for sport participation. The goals of this phase are to gradually increase strength, power, endurance, and neuromuscular control in order to prepare for a gradual return to sport. Specific criteria that must be met before entering this phase include full nonpainful ROM, no pain or tenderness, and strength that is 70% of the contralateral extremity.

Advanced strengthening activities during this phase include aggressive strengthening exercises, emphasizing high speed and eccentric contraction and plyometric activities. Elbow flexion exercises progress to emphasize eccentric control. The biceps muscle is an important stabilizer during the follow-through phase of overhead throwing, to eccentrically control the deceleration of the elbow and prevent pathological abutting of the olecranon within the fossa [2,24]. Elbow flexion can be performed with elastic tubing, to emphasize slow and fast speed, concentric and eccentric contractions. Furthermore, manual resistance may be applied for concentric and eccentric contractions of the elbow flexors. Aggressive strengthening exercises with weight machines are also incorporated during this phase. These most commonly begin with bench press, seated rowing, and front latissimus dorsi pull downs. The triceps are primarily exercised with a concentric contraction, because of the acceleration (muscle shortening) activity of the muscle during the acceleration phase of throwing.

Neuromuscular control exercises progress to include side-lying external rotation with manual resistance. Concentric and eccentric external rotation is performed against the clinician's resistance, with the addition of rhythmic sta-

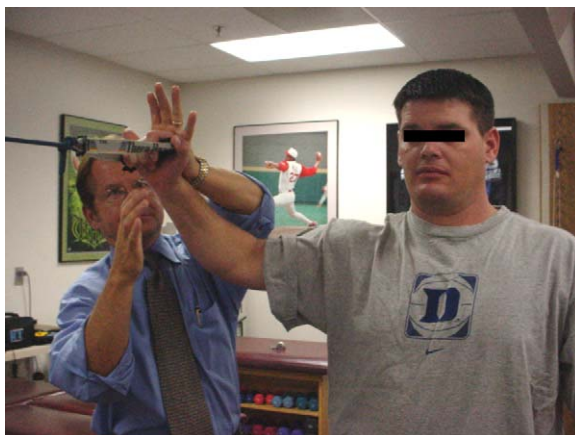

Fig. 5. External rotation at 90° abduction with exercise tubing, manual resistance, and rhythmic stabilizations.

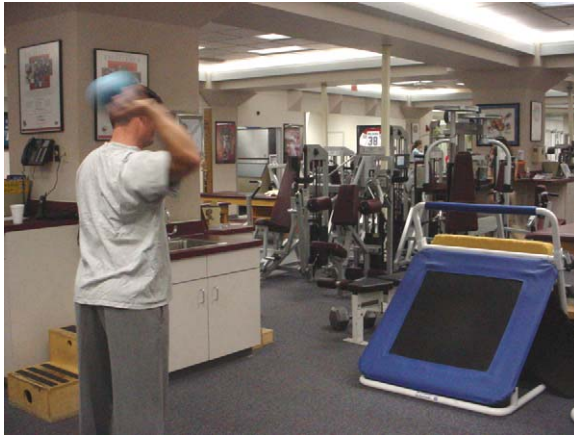

Fig. 6. Plyometric internal rotation throws at 90° abduction.

bilizations. This manual resistance exercise may be progressed to standing external rotation with exercise tubing at 0° and finally at 90° (Fig. 5).

Plyometric drills can be an extremely beneficial form of functional exercise for training the elbow in overhead athletes [14,25]. Plyometric exercises are performed using a weighted medicine ball during the later stages of this phase, in order to train the shoulder and elbow to develop and withstand high levels of stress. Plyometric exercises are initially performed with two hands performing a chest pass, side-to-side throw, and overhead soccer throw. These may progress to include one-hand activities such as 90/90 throws (Fig. 6), external and internal rotation throws at 0° of abduction (Fig. 7), and wall dribbles. Specific plyometric drills for the forearm musculature include wrist flexion flips (Fig. 8) and



Fig. 7. Plyometric internal rotation throws at 0° abduction.



Fig. 8. Plyometric wrist flips for the wrist flexors.

extension grips. The later two plyometric drills are an important component to an elbow rehabilitation program, emphasizing the forearm and hand musculature.

Phase IV—return-to-activity phase

The final phase of elbow rehabilitation, the return-to-activity phase, allows the athlete to progressively return to full competition using an interval return-to-throwing program. Other interval programs are used for the tennis player or golfer [26].

Before being allowed to begin the return-to-activity phase of rehabilitation, the athlete must exhibit full ROM, no pain or tenderness, a satisfactory isokinetic test, and a satisfactory clinical examination. Isokinetic testing is commonly used to determine the readiness of the athlete to begin an interval sport program [26]. Athletes are routinely tested at 180 and 300°/s. The bilateral comparison at 180°/s indicates the throwing arm's elbow flexion to be 10% to 20% stronger, and the dominant extensors 5% to 15% stronger than the nonthrowing arm.

Upon achieving the previously mention criteria to return to sport, the authors begin a formal interval sport program, as described by Reinold et al [26]. The program is outlined in Box 3. For the overhead thrower, we initiate a long-toss interval throwing program, beginning at 45 feet and gradually progressing to 120 or 180 feet (depending on player and position) [26]. Throwing should be performed without pain or significant increase in symptoms. We believe it is important for the overhead athlete to perform stretching and an abbreviated strengthening program before and after performing the interval sport program. Typically, our overhead throwers warm up, stretch, and perform one set of their

Box 3. Interval throwing program for baseball players: Phase I^{a,b}*45' phase**Step 1*

- Warm-up throwing
- 45' (25 throws)
- Rest 5–10 min.
- Warm-up throwing
- 45' (25 throws)

Step 2

- Warm-up throwing
- 45' (25 throws)
- Rest 5–10 min.
- Warm-up throwing
- 45' (25 throws)
- Rest 5–10 min.
- Warm-up throwing
- 45' (25 throws)

*60' phase**Step 3*

- Warm-up throwing
- 60' (25 throws)
- Rest 5–10 min.
- Warm-up throwing
- 60' (25 throws)

Step 4

- Warm-up throwing
- 60' (25 throws)
- Rest 5–10 min.
- Warm-up throwing
- 60' (25 throws)
- Rest 5–10 min.
- Warm-up throwing
- 60' (25 throws)

*90' phase**Step 5*

- Warm-up throwing
- 90' (25 throws)
- Rest 5–10 min.
- Warm-up throwing
- 90' (25 throws)

Step 6

- Warm-up throwing
- 90' (25 throws)
- Rest 5–10 min.
- Warm-up throwing
- 90' (25 throws)
- Rest 5–10 min.
- Warm-up throwing
- 90' (25 throws)

120' phase

Step 7

- Warm-up throwing
- 120' (25 throws)
- Rest 5–10 min.
- Warm-up throwing
- 120' (25 throws)

Step 8

- Warm-up throwing
- 120' (25 throws)
- Rest 5–10 min.
- Warm-up throwing
- 120' (25 throws)
- Rest 5–10 min.
- Warm-up throwing
- 120' (25 Throws)

150' phase

Step 9

- Warm-up throwing
- 150' (25 throws)
- Rest 5–10 min.
- Warm-up throwing
- 150' (25 throws)

Step 10

- Warm-up throwing
- 150' (25 throws)
- Rest 5–10 min.
- Warm-up throwing
- 150' (25 throws)
- Rest 5–10 min.
- Warm-up throwing
- 150' (25 throws)

*180' phase**Step 11*

- Warm-up throwing
- 180' (25 throws)
- Rest 5–10 min.
- Warm-up throwing
- 180' (25 throws)

Step 12

- Warm-up throwing
- 180' (25 throws)
- Rest 5–10 min.
- Warm-up throwing
- 180' (25 throws)
- Rest 5–10 min.
- Warm-up throwing
- 180' (25 throws)

Step 13

- Warm-up throwing
- 180' (25 throws)
- Rest 5–10 min.
- Warm-up throwing
- 180' (25 throws)
- Rest 5–10 min.
- Warm-up throwing
- 180' (20 throws)
- Rest 5–10 min.
- Warm-up throwing
- 15 throws, progressing from 90' to 120'

Step 14: Return to respective position or progress to step 15 below for flat-ground throwing

Flat-ground throwing for baseball pitchers

Step 15

- Warm-up throwing
- Throw 60' (10–15 throws)
- Throw 90' (10 throws)
- Throw 120' (10 throws)
- Throw 60' (flat ground) using pitching mechanics (20–30 throws)

Step 16

- Warm-up throwing
- Throw 60' (10–15 throws)
- Throw 90' (10 throws)
- Throw 120' (10 throws)

- Throw 60' (flat ground) using pitching mechanics (20–30 throws)
- Throw 60–90' (10–15 throws)
- Throw 60' (flat ground) using pitching mechanics (20 throws)

Progress to Phase II—throwing off the mound.

^a All throws should be on an arc with a crow-hop. Warm-up throws consist of 10–20 throws at approximately 30 feet. Throwing Program should be performed every other day, three times per week unless otherwise specified by your physician or rehabilitation specialist. Perform each step 2–3 times before progressing to next step.

^b 45 feet = 13.7 meters; 60 feet = 18.3 meters; 90 feet = 27.4 meters; 120 feet = 36.6 meters; 150 feet = 45.7 meters; 180 feet = 54.8 meters.

exercise program before throwing, followed by two additional sets of exercises after throwing [26]. This provides an adequate warm-up, and also ensures maintenance of necessary range of motion and flexibility of the shoulder joint. The following day, the throwers will exercise their scapular muscles, external rotators, and perform a core stabilization program.

Following the completion of a long-toss program, pitchers will progress to Phase II of the throwing program, throwing off a mound [26]. Phase II is outlined in Box 4. In Phase II, the number of throws, intensity, and type of pitch progress to gradually increase stress on the elbow and shoulder joints [26]. Generally, the pitcher begins at 50% intensity and gradually progresses to 75%, 90%, and 100% over a 4- to 6-week period of time. Breaking balls are initiated once the pitcher can throw 40 to 50 pitches at a minimum 80% intensity with symptoms.

Specific nonoperative rehabilitation guidelines

Medial epicondylitis and flexor-pronator tendinitis

Medial epicondylitis occurs due to changes within the flexor-pronator musculotendinous unit. Associated ulnar neuropathy has been reported in 25% to 60% of patients who have medial epicondylitis [27–29]. The underlying pathology is a microscopic or macroscopic tear within the flexor carpi radialis or pronator teres near the origin on the medial epicondyle. Throwers who exhibit flexor-pronator tendinitis may have an associated UCL injury. The tendinitis may develop as a secondary pathology or a false symptom. Thus, before initiating a rehabilitation program, it is important for the clinician to accurately clear the

Box 4. Interval throwing program: Phase II—throwing off the mound^a*Stage one: fastballs only*

- Step 1: Interval throwing^b — 15 throws off mound at 50%^c
- Step 2: Interval throwing—30 throws off mound at 50%
- Step 3: Interval throwing—45 throws off mound at 50%
- Step 4: Interval throwing—60 throws off mound at 50%
- Step 5: Interval throwing—70 throws off mound at 50%
- Step 6: 45 throws off mound at 50%; 30 throws off mound at 75%
- Step 7: 30 throws off mound at 50%; 45 throws off mound at 75%
- Step 8: 10 throws off mound at 50%; 65 throws off mound at 75%

Stage two: fastballs only

- Step 9: 60 throws off mound at 75%; 15 throws in batting practice
- Step 10: 50–60 throws off mound at 75%; 30 throws in batting practice
- Step 11: 45–50 throws off mound at 75%; 45 throws in batting practice

Stage three

- Step 12: 30 throws off mound at 75% warm-up; 15 Throws off mound at 50% (begin breaking balls); 45–60 throws in batting practice (fastball only)
- Step 13: 30 throws off mound at 75%; 30 breaking balls at 75%; 30 throws in batting practice
- Step 14: 30 throws off mound at 75%; 60–90 throws in batting practice (gradually increase breaking balls)
- Step 15: Simulated game, progressing by 15 throws per workout (pitch count)

^a All throwing off the mound should be done in the presence of a pitching coach or sport biomechanist, to stress proper throwing technique.

^b Use interval throwing 120'/36.6 m phase (Steps 1–5) as warm-up.

^c Percentage effort. Use speed gun to aid in effort control.

UCL of pathology. Furthermore, it may be beneficial to determine the number of episodes and chronicity of medial epicondylitis complaints. Patients who have long histories of medial epicondylitis may exhibit tendinosis, not tendonitis. Conversely, patients who have first-time episodes probably exhibit paratendonitis and tendinitis. The treatment is significantly different for each.

The nonoperative approach for treatment of epicondylitis (ie, tendinitis or paratendonitis) focuses on diminishing pain and inflammation associated with tendinitis, and then gradually improving muscular strength. Treatment for epicondylitis is summarized in [Box 5](#). The primary goals of rehabilitation are to control the applied loads and to create an environment for healing. The initial treatment consists of warm whirlpool, iontophoresis, stretching exercises, and light strengthening exercises to stimulate a repair response. Recently, the authors have used the disposable iontophoresis patch (Birchpoint Med, Oakdale, Minnesota) for tendinitis. The patch is worn for 20 to 24 hours with dexamethasone applied. The authors have observed excellent results clinically. High-voltage stimulation and cryotherapy are used following treatment, to decrease pain and postexercise inflammation. The athlete should be cautioned against excessive gripping activities. Conversely, patients who have tendinosis are treated with transverse friction massage, stretch techniques, and eccentric strengthening with gradually progressing loads, and warm modalities to promote tendon regeneration.

Once the patient's symptoms have subsided, an aggressive stretching and (high load, low repetitions) strengthening program with emphasis on eccentric contractions is initiated. Wrist flexion and extension activities should be performed initially with the elbow flexed 30° to 45°. A gradual progression through plyometric and throwing activities precedes the initiation of the interval throwing program. Because poor mechanics are often a cause of this condition, an analysis of sport mechanics and proper supervision through the interval throwing program are critical. If nonoperative treatment fails, the physician may perform a surgical debridement of the necrosection tissue.

Ulnar neuropathy

There are numerous theories regarding the cause of ulnar neuropathy of the elbow in throwing athletes. Ulnar nerve changes can result from tensile forces, compressive forces, or nerve instability. Any one or a combination of these mechanisms may be responsible for ulnar nerve symptoms.

A leading mechanism for tensile force on the ulnar nerve is valgus stress. This may be coupled with an external rotation-supination stress overload mechanism. The traction forces are further magnified when underlying valgus instability from UCL injuries is present. Ulnar neuropathy is often a secondary pathology of UCL insufficiency. Compression of the ulnar nerve is often due to hypertrophy of the surrounding soft tissues, or the presence of scar tissue. The nerve may also be trapped between the two heads of the flexor carpi ulnaris. Repetitive flexion and extension of the elbow with an unstable nerve can irritate or inflame the nerve.

Box 5. Epicondylitis rehabilitation protocol*Phase I—acute phase*

Goals: Decrease inflammation, promote tissue healing, retard muscular atrophy

Cryotherapy

Whirlpool

Stretching to increase flexibility: wrist extension/flexion, elbow extension/flexion, forearm supination/pronation

Isometrics: wrist extension/flexion, elbow extension/flexion, forearm supination/pronation

HVGS

Phonophoresis

Friction massage

Lontophoresis, with anti-inflammatory (ie, dexamethasone)

Avoid painful movements (ie, gripping, etc).

Phase II—subacute phase

Goals: improve flexibility, increase muscular strength/endurance, increase functional activities/return to function

Emphasize concentric/eccentric strengthening.

Concentration on involved muscle group

Wrist extension/flexion

Forearm pronation/supination

Elbow flexion/extension

Initiate shoulder strengthening (if deficiencies are noted).

Continue flexibility exercises.

May use counterforce brace

Continue use of cryotherapy after exercise/function.

Gradual return to stressful activities

Gradually reinstate once painful movements subside.

Phase III—chronic phase

Goals: improve muscular strength and endurance, maintain/enhance flexibility, gradual return to sport/high level activities

Continue strengthening exercises (emphasize eccentric/concentric).

Continue to emphasize deficiencies in shoulder and elbow strength.

Continue flexibility exercises.

Gradually decrease use of counterforce brace.
Use of cryotherapy as needed
Gradual return to sport activity
Equipment modification (grip size, string tension, playing surface)
Emphasize maintenance program.

The nerve may sublux or rest on the medial epicondyle, rendering it vulnerable to direct trauma.

There are three stages of ulnar neuropathy [30]. The first stage includes an acute onset of radicular symptoms. The second stage is manifested by a recurrence of symptoms as the athlete attempts to return to competition. The third stage is associated with persistent motor weakness and sensory changes. Once the athlete presents in the third stage of injury, conservative management may not be effective.

The nonoperative treatment of ulnar neuropathy focuses on diminishing ulnar nerve irritation, enhancing dynamic medial joint stability, and gradually returning the athlete to competition. Nonsteroidal anti-inflammatory drugs (NSAIDs) are often prescribed, and rehabilitation includes iontophoresis, disposable patch, and cryotherapy. Following the diagnosis of ulnar neuropathy, throwing athletes are instructed to discontinue throwing activities for at least 4 weeks, depending on the severity and chronicity of symptoms. The athlete progresses through the immediate motion and intermediate phases over the course of 4 to 6 weeks, with emphasis placed on eccentric and dynamic stabilization drills. Plyometric exercises are used to facilitate further dynamic stabilization of the medial elbow. The athlete is allowed to begin an interval throwing program when full, pain-free ROM and muscle performance are exhibited without neurological symptoms. The athlete may gradually return to play if progression through the interval throwing program does not reveal neurological symptoms.

Valgus extension overload

Valgus extension overload (VEO) occurs in repetitive sport activities such as throwing, during the acceleration or deceleration phase, as the olecranon wedges up against the medial olecranon fossa during elbow extension [4]. This mechanism may result in osteophyte formation, and potentially in loose bodies. Repetitive extension stress from the triceps may further contribute to this injury. There is often a certain degree of underlying valgus laxity of the elbow in these athletes, further facilitating osteophyte formation through compression of the radiocapitellar joint and the posteromedial elbow [31,32]. Overhead athletes typically present with pain at the posteromedial aspect of the elbow that is exacerbated with forced extension and valgus stress.

A conservative treatment approach is often attempted before considering surgical intervention. Initial treatment involves relieving the posterior elbow of pain

and inflammation. As symptoms subside and ROM normalizes, dynamic stabilization and strengthening exercises are initiated. Emphasis is placed on improving eccentric strength of the elbow flexors, in an attempt to control the rapid extension that occurs at the elbow during athletics. Forceful triceps extension, especially performed rapidly, are progressively integrated. Manual resistance exercises of concentric and eccentric elbow flexion are performed, as is elbow flexion with exercise tubing. The athlete's throwing mechanics should be carefully assessed to determine if mechanical faults are causing the VEO symptoms.

Ulnar collateral ligament injury

Injuries to the UCL are becoming increasingly common in overhead throwing athletes, although the higher incidence of injury may be due to our increased ability to diagnose these injuries. The elbow experiences a tremendous amount of valgus stress during overhead throwing. These stresses approach the ultimate failure load of the ligament with each throw. The repetitive nature of overhead throwing activities such as baseball pitching, javelin throwing, and football passing further increases the susceptibility to UCL injury, by exposing the ligament to repetitive microtraumatic forces. The stresses on the UCL are probably greater with specific types of pitches, such as the slider and split-fingered pitch.

Conservative treatment is attempted with partial tears and sprains of the UCL, although surgical reconstruction may be warranted for complete tears, or if nonoperative treatment is unsuccessful. The authors' nonoperative rehabilitation program is outlined in **Box 6**. Range of motion is initially permitted in a nonpainful arc of motion, usually from 10° to 100°, to allow for a decrease in inflammation and the alignment of collagen tissue. A brace may be used to restrict motion and to prevent valgus loading. Isometric exercises are performed for the shoulder, elbow, and wrist to prevent muscular atrophy. Ice and anti-inflammatory medications are prescribed to control pain and inflammation.

Range of motion of both flexion and extension is gradually increased by 5° to 10° per week during the second phase of treatment, or as tolerated. Full ROM should be achieved by at least 3 to 4 weeks. Elbow flexion/extension motion is encouraged, due to collagen formation and alignment. The authors attempt to control valgus loading onto the elbow joint in order to control stress on the UCL. Rhythmic stabilization exercises are initiated to develop dynamic stabilization and neuromuscular control of the upper extremity. As dynamic stability is advanced, isotonic exercises are incorporated for the entire upper extremity.

The advanced strengthening phase is usually initiated at 6 to 7 weeks post-injury. During this phase, the athlete is progressed to the thrower's ten isotonic strengthening program (see **Fig. 2**), and plyometric exercises are slowly initiated. An interval return-to-throwing program is initiated once the athlete regains full motion, adequate strength, and dynamic stability of the elbow. The athlete is allowed to return to competition following the asymptomatic completion of the interval sport program. If symptoms reoccur during the interval throwing program, it is usually at longer distances, at greater intensities, or with off-the-

Box 6. Conservative treatment following ulnar collateral sprains of the elbow

Immediate motion phase (weeks 0–2)

Goals: increase range of motion, promote healing of ulnar collateral ligament; retard muscular atrophy; decrease pain and inflammation

ROM

1. Brace (optional); nonpainful ROM [20°–90°]
2. Active assisted range of motion (A/AROM), PROM elbow and wrist (nonpainful range)

Exercises

1. Isometrics—wrist and elbow musculature
2. Shoulder strengthening (no external rotation strengthening)

Ice and compression

Intermediate phase (weeks 3–6)

Goals: increase range of motion, improve strength/endurance, decrease pain and inflammation, promote stability

ROM: gradually increase motion to 135° (increase 100° per week).

Exercises: initiate isotonic exercises.

1. Wrist curls
2. Wrist extensions
3. Pronation/supination
4. Biceps/triceps
5. Dumbbells
 - External rotation
 - Deltoid
 - Supraspinatus
 - Rhomboids
 - Internal rotation

Ice and compression

Advanced phase (weeks 7–12)

Criteria to progress

1. Full ROM
2. No pain or tenderness
3. No increase in laxity
4. Strength 4/5 of elbow flexor/extensor

Goals: increase strength, power and endurance; improve neuro-muscular control; initiate high-speed exercise drills

Exercises

1. Initiate exercise tubing, shoulder program.
2. Thrower's ten program
3. Biceps/triceps program
4. Supination/pronation
5. Wrist extension/flexion
6. Plyometrics throwing drills

*IV. Return to Activity Phase (week 12 through 14)**Criteria to progress to return to throwing*

1. Full, nonpainful ROM
2. No Increase in laxity
3. Isokinetic test fulfills criteria
4. Satisfactory clinical examination

Exercises

1. Initiate interval throwing.
2. Continue thrower's ten program.
3. Continue plyometrics.

mound throwing. If symptoms persist, the athlete is reassessed, and surgical intervention is considered.

Osteochondritis dessicans

Osteochondritis dessicans of the elbow may develop due to the valgus strain on the elbow joint, which produces not only medial tension, but also a lateral compressive force [33]. This is observed as the capitellum of the humerus compresses with the radial head. Patients often complain of lateral elbow pain upon palpation, and valgus stress. Morrey [34] described a three-stage classification of pathological progression. Stage one describes patients without evidence of subchondral displacement or fracture. Stage two refers to lesions showing evidence of subchondral detachment or articular cartilage fracture. Stage three lesions involve detached osteochondral fragments, potentially resulting in intra-articular loose bodies. Nonsurgical treatment is attempted for stage one patients only, and consists of relative rest and immobilization until elbow symptoms have resolved.

Nonoperative treatment includes 3 to 6 weeks of immobilization at 90° of elbow flexion; however, ROM activities for the shoulder, elbow, and wrist are performed three to four times a day. As symptoms resolve, a strengthening program is initiated with isometric exercises. Isotonic exercises are included after approximately 1 week of isometric exercise. Aggressive high-speed, eccentric, and plyometric exercises are progressively included, to prepare the athlete for the start of an interval throwing program.

If nonoperative treatment fails or evidence of loose bodies exist, surgical intervention, including arthroscopic abrading and drilling of the lesion with

fixation or removal of the loose body, is indicated [35]. Long-term follow-up studies regarding the outcome of patients undergoing surgery to drill or reattach the lesions have not reported favorable results, suggesting that prevention and early detection of symptoms may be the best form of treatment.

Little League elbow

Pain of the medial elbow is common in adolescent throwers. The medial epicondyle physis is subject to repetitive tensile and valgus forces during the arm-cocking and acceleration phases of throwing. These forces may result in microtraumatic injury to the physis, with potential fragmentation, hypertrophy, separation of the epiphysis, or avulsion of the medial epicondyle. Treatment varies based on the extent of injury.

In the absence of an avulsion, a rehabilitation program similar to that in the nonoperative UCL program is initiated. Emphasis is placed initially on the reduction of pain and inflammation, and the restoration of motion and strength. Strengthening exercises are performed in a gradual fashion. First isometrics are performed, then light isotonic. No heavy lifting is permitted for 12 to 14 weeks. An interval throwing program is initiated as tolerated when symptoms subside.

In the presence of a nondisplaced or minimally displaced avulsion, a brief period of immobilization for approximately 7 days is encouraged, followed by a gradual progression of range of motion, flexibility, and strength. An interval throwing program is usually allowed at week 6 to 8. If the avulsion is displaced, an open reduction, internal fixation procedure may be required.

Specific postoperative rehabilitation guidelines

Ulnar nerve transposition

At the American Sports Medicine Institute, transpositioning of the ulnar nerve is performed in a subcutaneous fashion, using fascial slings. Caution is taken to not overstress the soft-tissue structures involved with relocating the nerve while healing occurs [14]. The rehabilitation following an ulnar nerve transposition is outlined in **Box 7**. A posterior splint at 90° of elbow flexion is used for the first week postoperatively, to prevent excessive extension ROM and tension on the nerve. The splint is discharged at the beginning of week 2, and light ROM activities are initiated. Full ROM is usually restored by weeks 3 to 4. Gentle isotonic strengthening is begun during week 4 and progressed to the full thrower's ten program by 6 weeks following surgery. Aggressive strengthening, including eccentric and plyometric training, is incorporated by weeks 7 to 8, and an interval throwing program at weeks 8 to 9, if all previously outlined criteria are met. A return to competition usually occurs between weeks 12 and 16 postoperatively.

Box 7. Postoperative rehabilitation following ulnar nerve transposition*Phase I. Immediate postoperative phase (week 0–1)*

Goals: allow soft-tissue healing of relocated nerve, decrease pain and inflammation, retard muscular atrophy

Week 1

Posterior splint at 90° elbow flexion with wrist free for motion (sling for comfort)
Compression dressing
Exercises such as gripping exercises, wrist ROM, shoulder isometrics

Week 2

Remove posterior splint for exercise and bathing.
Progress elbow ROM (PROM 15° to 120°).
Initiate elbow and wrist isometrics.
Continue shoulder isometrics.

Phase II. Intermediate phase (weeks 3–7)

Goals: restore full, pain-free range of motion; improve strength, power, and endurance of upper extremity musculature; gradually increase functional demands

Week 3

Discontinue posterior splint.
Progress elbow ROM; emphasize full extension.
Initiate flexibility exercise for wrist extension/flexion, forearm supination/pronation, and elbow extension/flexion.
Initiate strengthening exercises for wrist extension/flexion, forearm supination/pronation, elbow extensors/flexors, and a shoulder program.

Week 6

Continue all exercises listed above.
Initiate light sport activities.

Phase III. Advanced strengthening phase (weeks 8–12)

Goals: increase strength, power, endurance; gradually initiate sporting activities

Week 8

Initiate eccentric exercise program.

Initiate plyometric exercise drills.

Continue shoulder and elbow strengthening and flexibility exercises.

Initiate interval throwing program.

Phase IV. Return-to-activity phase (weeks 12–16)

Goal: gradually return to sporting activities

Week 12

Return to competitive throwing.

Continue thrower's ten exercise program.

Posterior olecranon osteophyte excision

Surgical excision of posterior olecranon osteophytes is performed arthroscopically, using an osteotome or motorized burr. Approximately 5 to 10 mm of the olecranon tip is removed concomitantly, and a motorized burr is used to contour the coronoid, olecranon tip, and fossa to prevent further impingement with extreme flexion and extension [36]. Caution is exercised not to remove too much bone and destabilize the elbow, which results in increased loads on the UCL during forceful throwing [37].

The rehabilitation program following arthroscopic posterior olecranon osteophyte excision is slightly more conservative in restoring full elbow extension secondary to postsurgical pain. ROM is progressed within the patient's tolerance; by 10 days postoperative the patient should exhibit at least 15° to 105/110° of ROM, and 5/10° to 115° by day 14. Full ROM (0°–145°) is typically restored by day 20 to 25 postsurgery. The rate of ROM progression is most often limited by osseous pain and synovial joint inflammation, usually located at the top of the olecranon.

The strengthening program is similar to the previously discussed progression. Isometrics are performed for the first 10 to 14 days, and isotonic strengthening from week 2 to 6. The full thrower's ten program is initiated by week 6. An interval throwing program is included by week 10 to 12. The rehabilitation focus is similar to the nonoperative treatment of valgus extension overload. Emphasis is placed on eccentric control of the elbow flexors and dynamic stabilization of the medial elbow.

Andrews and Timmerman [38] reported on the outcome of elbow surgery in 72 professional baseball players. Sixty-five percent of these athletes exhibited a posterior olecranon osteophyte, and 25% of the athletes who underwent an isolated olecranon excision later required an ulnar collateral ligament recon-

struction [38]. This may suggest that subtle medial instability may accelerate osteophyte formation.

Ulnar collateral ligament reconstruction

Surgical reconstruction of the UCL attempts to restore the stabilizing functions of the anterior bundle of the UCL [39]. The palmaris longus or gracilis graft source is taken, and passed in a figure-8 pattern through drill holes in the sublime tubercle of the ulna and the medial epicondyle [39]. An ulnar nerve transposition is often performed at the time of reconstruction [39].

The rehabilitation program the authors currently use following ulnar collateral ligament reconstruction is outlined in **Box 8**. The athlete is placed in a posterior splint with the elbow immobilized at 90° of flexion for the first 7 days postoperatively. This allows adequate healing of the UCL graft and soft-tissue slings involved in the nerve transposition. The patient is allowed to perform wrist ROM and gripping and submaximal isometrics for the wrist and elbow. The patient is progressed from the posterior splint to an elbow ROM brace, which is adjusted to allow ROM from 30° to 100° of flexion. Motion is increased by 5° of extension and 10° of flexion thereafter, to restore full ROM by the end of week 6 (0°–145°). The brace is discontinued by weeks 5 to 6.

Isometric exercises progress to include light-resistance isotonic exercises at week 4 and the full thrower's ten program by week 6. Progressive resistance exercises are incorporated at week 8 to 9. Focus is again placed on developing dynamic stabilization of the medial elbow. Due to the anatomical orientation of the flexor carpi ulnaris and flexor digitorum superficialis overlaying the UCL, isotonic and stabilization activities for these muscles may assist the UCL in stabilizing valgus stress at the medial elbow [40]. Thus, concentric strengthening of these muscles is performed.

Aggressive exercises involving eccentric and plyometric contractions are included in the advanced phase, usually weeks 9 through 14. Two-hand plyometric drills are performed at week 10, one-hand drills from weeks 12 to 13. An interval throwing program is allowed at week 16 postoperatively. In most cases, throwing from a mound is advanced to within 4 to 6 weeks following the initiation of an interval throwing program, and a return to competitive throwing occurs at approximately 9 months following surgery.

Arthroscopic arthrolysis

Many of the previously pathologies that have been discussed have involved motion loss as a primary complication. The elbow joint is one of the most frequent joints to develop motion loss [16,41]. Following injury or surgery, the elbow joint flexes in response to pain and hemarthrosis. The periarticular soft tissue and joint capsule become shortened and fibrotic, and loss of motion develops. An arthroscopic arthrolysis may be necessary in some patients who do not respond to conservative treatment.

Box 8. Postoperative rehabilitation following chronic ulnar collateral ligament reconstruction using autogenous graft

Phase I. Immediate postoperative phase (weeks 0–3)

Goals: protect healing tissue, decrease pain/inflammation, retard muscular atrophy

Week 1

Posterior splint at 90° elbow flexion
Wrist active range of motion (AROM) extension/flexion
Elbow compression dressing (2 to 3 days)
Exercises such as gripping exercises, wrist ROM, shoulder isometrics (except shoulder external rotation [ER]), biceps isometrics
Cryotherapy

Week 2

Application of functional brace 30° to 100°
Initiate wrist isometrics.
Initiate elbow flexion/extension isometrics.
Continue all exercises listed above.

Week 3

Advance brace 15° to 110° (gradually increase ROM; 5° extension/10° flexion per week).

Phase II. Intermediate phase (weeks 4–8)

Goals: gradual increase in range of motion, promote healing of repaired tissue, regain and improve muscular strength

Week 4

Functional brace set (10° to 120°)
Begin light resistance exercises for arm (1 lb): wrist curls, extensions, pronation/supination, elbow extension/flexion.
Progress shoulder program, emphasizing rotator cuff strengthening (avoid ER until week 6).

Week 6

Functional brace set (0° to 130°); AROM 0°–140° (without brace)
Progress elbow strengthening exercises.

Initiate shoulder external rotation strengthening.
Progress shoulder program.

Phase III. Advanced strengthening phase (weeks 9–13)

Goals: increase strength, power, endurance; maintain full elbow ROM; gradually initiate sporting activities

Week 9

Initiate eccentric elbow flexion/extension.
Continue isotonic program; forearm and wrist.
Continue shoulder program—thrower's ten program.
Manual resistance, diagonal patterns
Initiate plyometric exercise program.

Week 11

Continue all exercises listed above.
May begin light sport activities (eg, golf, swimming).

Phase IV. Return-to-activity phase (weeks 14–26)

Goals: continue to increase strength, power, and endurance of upper extremity (UE) musculature; gradual return to sport activities

Week 14

Initiate interval throwing program (Phase I).
Continue strengthening program.
Emphasis on elbow and wrist strengthening and flexibility exercises

Weeks 22–26

Return to competitive throwing.

During the first postoperative week, the patient is instructed to perform elbow and wrist ROM exercises hourly. Treatment to regain ROM at this time is cautiously aggressive [42]. Full motion should be obtained quickly; however, a pace that does not cause additional inflammation of the joint capsule is necessary in order to avoid further pain and reflexive splinting. Low-load, long-duration stretching has been an extremely beneficial treatment technique for the authors clinically. Full passive ROM is usually restored by days 10 to 14, or by 21 days at the latest.

Isometric strengthening is begun during week 2, and progresses to isotonic dumbbell exercises during the third to fourth week. Strengthening exercises are increased as tolerated by the patient. Emphasis during the later phases of rehabilitation continues to be placed on maintaining motion. Patients are educated to continue a motion maintenance program several times per day and before and after sport activities for at least 2 to 3 months following surgery.

Summary

The elbow joint is a common site of injury in the overhead athlete, due to the repetitive microtraumatic injuries observed during the act of throwing. Rehabilitation of the elbow, whether postinjury or postsurgical, must follow a progressive and sequential order to ensure that healing tissues are not overstressed. A rehabilitation program that limits immobilization, achieves full range of motion early, progressively restores strength and neuromuscular control, and gradually incorporates sport-specific activities is essential to successfully return athletes to their previous levels of competition as quickly and safely as possible.

References

- [1] Werner SL, Fleisig GS, Dillman CJ, et al. Biomechanics of the elbow during baseball pitching. *J Orthop Sports Phys Ther* 1993;17:274–8.
- [2] Fleisig GS, Escamilla RF. Biomechanics of the elbow in the throwing athlete. *Oper Tech Sports Med* 1996;4(2):62–8.
- [3] Dillman CJ, Smutz P, Werner SL. Valgus extension overload in baseball pitching. *Med Sci Sports Exerc* 1991;23:355.
- [4] Wilson FD, Andrews JR, Blackburn TA, et al. Valgus extension overload in pitching elbow. *Am J Sports Med* 1983;11:83–8.
- [5] Andrews JR, Craven WM. Lesions of the posterior compartment of the elbow. *Clin Sports Med* 1991;10:637–52.
- [6] Coutts R, Rothe C, Kaita J. The role of continuous passive motion in the rehabilitation of the total knee patient. *Clin Orthop* 1981;159:126–32.
- [7] Dehne E, Tory R. The treatment of joint injuries by immediate mobilization based upon the spiral adaptation concept. *Clin Orthop* 1971;77:218–32.
- [8] Haggmark T, Eriksson E. Cylinder or mobile cast brace after knee ligament surgery: a clinical analysis and morphologic and enzymatic studies of changes of the quadriceps muscle. *Am J Sports Med* 1979;7:48–56.
- [9] Noyes FR, Mangine RE, Barber SE. Early knee motion after open and arthroscopic anterior cruciate ligament reconstruction. *Am J Sports Med* 1987;15:149–60.
- [10] Perkins G. Rest and motion. *J Bone Joint Surg* 1954;35(B):521–39.
- [11] Salter RB, Hamilton HW, Wedge JH. Clinical application of basic research on continuous passive motion on healing of full thickness defects in articular cartilage. *J Bone Joint Surg* 1980;62A:1232–51.
- [12] Salter RB, Hamilton HW, Wedge JH. Clinical application of basic research on continuous

- passive motion for disorders and injuries of synovial joints. A preliminary report of a feasibility study. *J Orthop Res* 1984;1:325–42.
- [13] Tipton CM, Mathies RD, Martin RF. Influence of age and sex on strength of bone-ligament junctions in knee joints in rats. *J Bone Joint Surg* 1978;60(A):230–6.
- [14] Wilk KE, Arrigo C, Andrews JR. Rehabilitation of the elbow in the throwing athlete. *J Orthop Sports Phys Ther* 1993;17(6):305–17.
- [15] Akeson WH, Amiel D, Woo SLY. Immobilization effects on synovial joints. The pathomechanics of joint contracture. *Biorheology* 1980;17:95–107.
- [16] Green DP, McCoy H. Tumbuckle orthotic correction of elbow flexion contractures. *J Bone Joint Surg* 1979;61(A):1092.
- [17] Nirschl RP, Morrey BF. Rehabilitation. In: Morrey BF, editor. *The elbow and its disorders*. Philadelphia: WB Saunders; 1985. p. 147–52.
- [18] Kottke FJ, Pauley DL, Ptak RA. The rationale of prolonged stretching for connective tissue. *Arch Phys Med Rehabil* 1966;47:345–52.
- [19] Sapega AA, Quedenfeld TC, Moyer RA, Butler RA. Biophysical factors in range of motion exercise. *Arch Phys Med Rehabil* 1976;57:122–6.
- [20] Warren CG, Lehmann JF, Koblanski JN. Elongation of rat tail tendon: effect of load and temperature. *Arch Phys Med Rehabil* 1971;52:465–74.
- [21] Warren CG, Lehmann JF, Koblanski JN. Heat and stretch procedures: an evaluation using rat tail tendon. *Arch Phys Med Rehabil* 1976;57:122–6.
- [22] Maitland GD. *Vertebral manipulation*. London: Butterworths; 1977. p. 84–105.
- [23] Wyke BD. The neurology of joints. *Ann R Coll Surg Engl* 1966;41:25–9.
- [24] Andrews JR, Frank W. Valgus extension overload in the pitching elbow. In: Andrews JR, Zarins B, Carson WB, editors. *Injuries to the throwing arm*. Philadelphia: WB Saunders; 1985. p. 250–7.
- [25] Wilk KE, Voight M, Keirns MD, et al. Plyometrics for the upper extremities: theory and clinical application. *J Orthop Sports Phys Ther* 1993;17:225–39.
- [26] Reinold MM, Wilk KE, Reed J, et al. Internal sport programs: guidelines for baseball, tennis, and golf. *J Orthop Sports Phys Ther* 2002;32:293–8.
- [27] Gabel GT, Morrey BF. Medial epicondylitis: surgical management, influence of ulnar neuropathy. *J Shoulder Elbow Surg* 1994;3:511–6.
- [28] Nirschl RP. Medial tennis elbow, surgical treatment. *Orthop Trans* 1983;7:298.
- [29] Vangsness T, Jobe F. The surgical treatment of medial epicondylitis. *Orthop Trans* 1988;12:733.
- [30] Alley RM, Pappas AM. Acute and performance related injuries of the elbow. In: Pappas AM, editor. *Upper extremity injuries in the athlete*. New York: Churchill Livingstone; 1995. p. 339–64.
- [31] Anderson K. Elbow arthritis and removal of loose bodies and spurs and techniques for restoration of motion. In: Altchek DW, Andrews JR, editors. *The athlete's elbow*. Philadelphia: Lippincott Williams & Wilkins; 2001. p. 219–30.
- [32] Azar FM, Andrews JR, Wilk KE, et al. Operative treatment of ulnar collateral ligament injuries of the elbow in athletes. *Am J Sports Med* 2000;28:16–23.
- [33] Andrews JR, Whiteside JA. Common elbow problems in the athlete. *J Orthop Sports Phys Ther* 1993;17(6):289–95.
- [34] Morrey BF. Osteochondritis Dissecans. In: DeLee JC, Drez D, editors. *Orthopedic sports medicine*. Philadelphia: Saunders; 1994. p. 908–12.
- [35] Roberts W, Hughes R. Osteochondritis dissecans of the elbow joint: a clinical study. *J Bone Joint Surg* 1950;32(B):348–60.
- [36] Martin SD, Baumgarten TE. Elbow injuries in the throwing athlete: diagnosis and arthroscopic treatment. *Oper Tech Sports Med* 1996;4(2):100–8.
- [37] Andrews JR, Heggland EJ, Fleisig GS, et al. Relationship of ulnar collateral ligament strain to amount of medial olecranon osteotomy. *Am J Sports Med* 2001;29:716–21.
- [38] Andrews JR, Timmerman L. Outcome of elbow surgery in professional baseball players. *Am J Sports Med* 1995;23:245–50.
- [39] Andrews JR, Jelsma RD, Joyse ME, Timmerman LA. Open surgical procedures for injuries to the elbow in throwers. *Oper Tech Sports Med* 1996;4(2):109–13.

- [40] Davidson PA, Pink M, Perry J. Functional anatomy of the flexor pronator muscle in group relation to the medial collateral ligament of the elbow. *Am J Sports Med* 1995;23:245–50.
- [41] Timmerman LA, Andrews JR. Undersurface tears of the ulnar collateral ligament in baseball players. A newly recognized lesion. *J Sports Med* 1994;22:33–6.
- [42] Wilk KE. Rehabilitation of the elbow following arthroscopic surgery. In: Andrews JR, Soffer SR, editors. *Elbow arthroscopy*. St. Louis (MO): Mosby; 1994. p. 109–16.